

AUTOCHTHONOUS HYDATID DISEASE IN TENNESSEE

B. H. WEBSTER, M. D.

Mid-State Medical Center, Nashville, Tennessee

Hydatid Disease or Echinococcosis is a disease entity of relatively low endemicity but high mortality and morbidity. Fortunately it is rare. It has been estimated by Katz (2) that fewer than 1% of the clinicians in America have treated a case of Echinococcosis.

Two species of *Echinococcus* parasitize man as hydatids: *E. granulosus* and *E. multilocularis*. Of the latter, only two cases have been found in the literature (5, 6).

PARASITOLOGY

Dogs are definitive hosts. Sheep, man and various other mammals are intermediate hosts, the sheep being the most important. Man acquires the infection from the dog. Horses and cattle may be more heavily infested than sheep, but apparently harbor fewer fertile hydatids.

The adult worm averages 3.4 mm in length. There is a scolex and 3 proglottids, the hindmost being the only gravid one. The scolex has a prominent rostellum with 32-38 hooklets in 2 rings. The embryophores measure 38 x 35 microns, the oncospheres 28 x 25 microns. These are excreted in the feces of the dogs, and are sometimes accompanied by gravid proglottids.

EPIDEMIOLOGY

The intermediate host ingests embryophores, the wall disintegrates, and the oncospheres are freed and penetrate the intestinal walls, entering the lymphatics or venous circulation. Enroute to the heart the oncospheres are filtered out by the hepatic circulation. If they pass through the liver, they are filtered out by the pulmonary capillaries (8, 10) and possibly by other organs. Primary venous infection of the liver or lung may occur, the liver infection being predominant (9).

It is estimated by Dévé (11) that the oncospheres reach the systemic circulation in 16% of primary infections. This represents the primary arterial infection with ensuing invasion of the spleen, kidneys, eyes, brain, bone, et cetera.

MORBID ANATOMY

The adult tapeworms live in the intestines of dogs and other carnivores, but not of man. The larvae, which are cyst-like, characterized by thin marginal cytoplasm enclosing clear yellow fluid, require 5-7 months to reach a size of 10-15 mm. Multiple concentric hyaline laminae formed from a proliferating fibroblastic sheath surround a germinal protoplasmic rim.

Inside the hydatid, groups of cells called brood capsules bud from the germinal layer. Scolices develop from each germinal layer of the brood capsules. The head is invaginated. Detached brood capsules float

within the hydatid fluid, laminate, and become daughter cysts which develop their own brood capsules. Enormous sizes may occur. They may remain viable for many years, or death may be followed by calcification. The slow growth may not produce symptoms until as long as 4 to 8 years following infection. Perforation of the hydatid cyst may lead to super-sensitivity reactions, such as urticaria, pneumonia, and eosinophilia.

Large primary hepatic, pulmonic, or other hydatids may appear. Hepatic cysts may perforate the diaphragm, leading to pleural effusion, empyema, or pneumonitis, and secondary hydatids. Subphrenic abscess, bronchopleural fistula, lung abscess, and perforation into the pericardium may occur. Brain and osseous hydatids occur less often.

INCIDENCE

A survey made by the National Research Council of the National Academy of Sciences (1) showed that only 21 of the 169 countries and territories interrogated reported human hydatidosis. Only 1 country of the 46 in the Caribbean, Central and South America acknowledged its presence. Reports were forthcoming from 9 of 58 countries in Africa, 4 of 18 in Southwest Asia, 5 of 24 countries in South-Central and Southwest Asia, and 2 of 23 countries in Oceania.

Official reports (1) showed 14,770 cases of hydatid disease in 1957. Two percent of these were in Africa, 1% in Southwest Asia. There is a general absence of data from the Americas. Consequently, the real incidence of Hydatid Disease is unknown. The incidence where the disease is endemic may be high. The disease is well-known in South America, but not reportable.

Only 40 autochthonous cases (2) are known in the United States. However, it is not a reportable disease. No deaths have been reported in Tennessee in the past 10 years (3). Massachusetts General Hospital (4) listed 79 cases in the 100 year period from 1856-1956. Katz and Pan (2) reviewed 566 cases in the United States literature, but only 38 of these patients were thought to have been autochthonous.

CASE REPORTS

Three cases of Echinococcosis (Table 1) in native-born middle Tennesseans have been encountered by the author. None of these patients has been outside continental United States; two have not been outside Tennessee. All were reared on farms. One was a housewife, one, a farmer and construction worker, and the other, a student. All were Caucasian; their ages were 14, 23, and 68 years.

Case I was a 68 year old woman who was asymptomatic, but had radiologic evidence of a hepatic and

Table 1

	Case Numbers		
	1.	2.	3.
Age	68	23	14
Sex	Female	Male	Male
Color	White	White	White
Occupation	Rural Hwfe.	Farmer, const.	Rural student
Years followed	20	7	5
Ech. Cut. Test	4+	4+	
Histoplasmin	0	0	0
Tuberculin	0	0	0
Coccidioidin	0	0	0
Sputum studies	0	Bile	0
Stool	0	0	0
Hemogglutination		0	
Bentonite		0	
Ech. C. F. test		4+	
Leukocytosis	6400	7800-14,200	5400
Eosinophilia	3-6%	10-24%	1%
Surgery	None	2 Hep. Res., 1 Pulm. Res.	Pulm. res.
Path. report		Hydatid	Hydatid
Radiologic Dx	Cysts (liver, lungs)	Cysts (liver, lung)	Coin lesion
Symptomatology	None	R.U.Q. pain, chest pain, hemoptysis.	Chest pain
Treatment		Hep. and Pulm. Res.	Pulm. Seg.
Necropsy	Hydatids, C. V. A.	Living	Living
Cause of death	C. V. A.	Living	Living

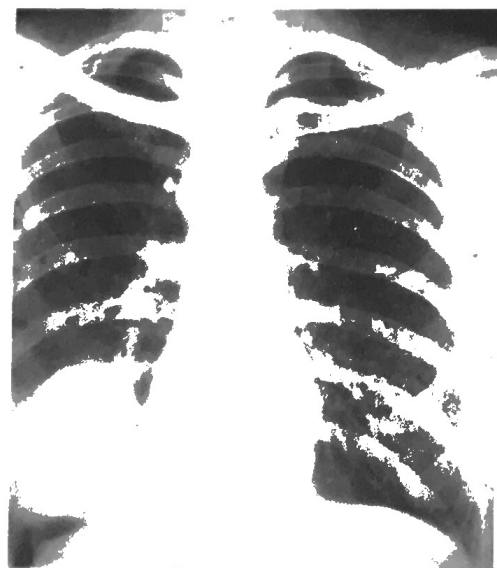


Fig. 1 A. Postero-lateral view.
Chest film showing hydatid cyst about 3x4 cm. in the right lower lobe.

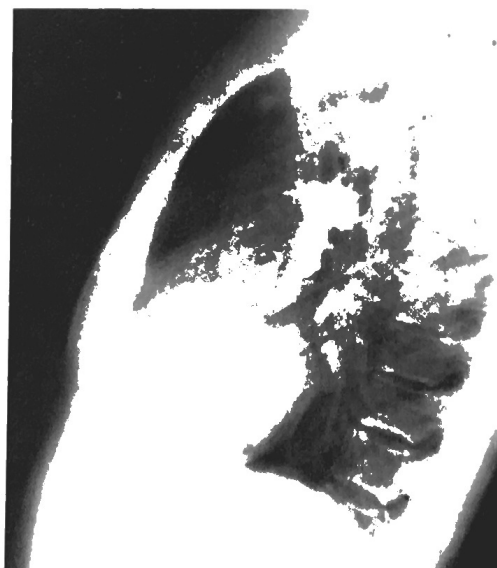


Fig. 1 B. Lateral view.

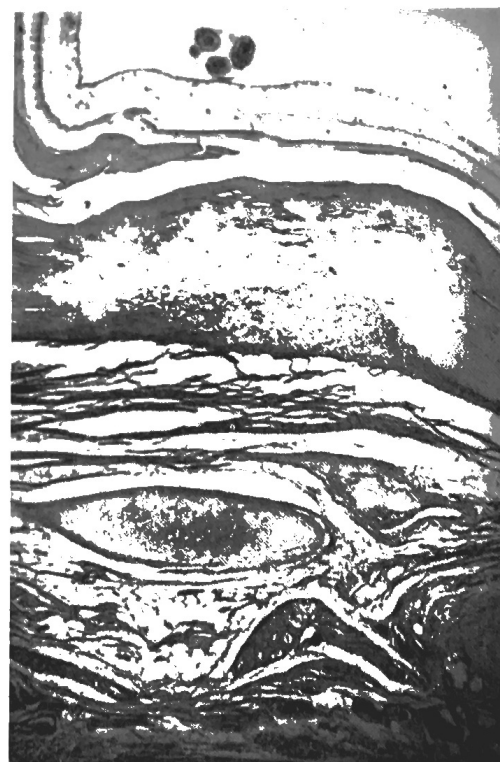

Fig. 2 A. H. & E. x 20

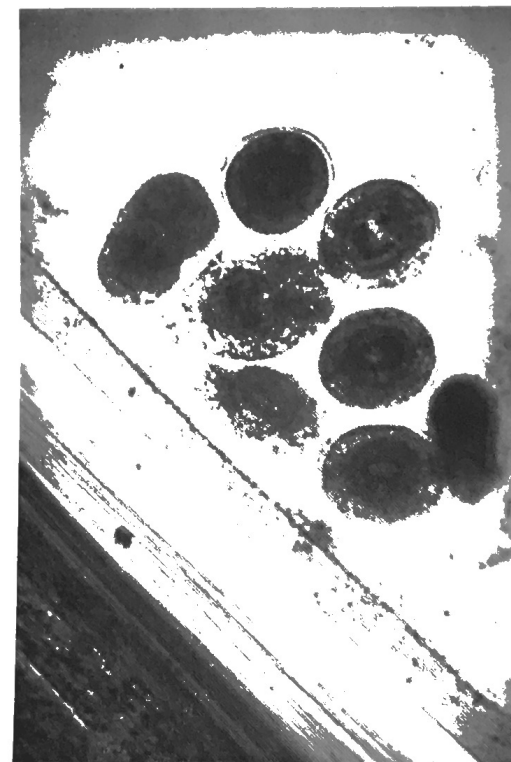


Fig. 2 B. H. & E. x 40

Photomicrograph, pulmonary, revealing typical brood capsule and scolices.

right lower pulmonic lobe calcified unilocular irregular cyst containing small particles. This patient whose case was followed for 20 years, showed a positive Cutaneous Hydatid Test on 4 occasions, Eosinophilia of 10-24%, and recurrent urticaria. She died of a cerebrovascular accident. Necropsy revealed cardiovascular arteriosclerotic heart disease and an eccentrically calcified unilocular cyst (measuring 2 x 3 cm) in the right lobe of the liver and another (measuring 3 x 4 cm) in right lower lobe of the lung (Fig. 1).

Case II. A 23 year old farmer and construction worker complained of right upper quadrant pain, flatulence, nausea, and subscapular discomfort for 4-5 years. Cholecystograms revealed low-functioning gall bladder. In August, 1956, exploratory laparotomy for suspected cholecystitis revealed a fluctuant cyst in the right lobe of the liver near the gall bladder. Sections showed a hydatid cyst, measuring 3 x 4 cm, with many brood cysts. In February, 1957, 2 hydatid cysts were found in the right side of the liver, and were resected. Approximately two weeks later, the right pulmonic base was segmentally resected because of a painful infiltra-

tion. It revealed hydatid cysts with a surrounding pneumonitis. The patient had symptoms of chest pain, dyspnea, fever, hemoptysis, and bile in the sputum. An Echinococcus complement fixation test was strongly positive at this time.

The patient was treated with large amounts of Furazolidin over a period of two months. Symptoms subsided. The Bentonite flocculation test, and hemogglutination tests were negative 3-3-60 and 2-1-62. Eosinophile count ranged from 3-6% and the leukocyte count from 7800 to 14,200.

Case III. A 14 year old rural student developed a solitary painful nodule in the right lower lobe of the lung. There were no other symptoms. Chest film revealed a "coin lesion", non-diagnostic. Tuberculin, histoplasmin, and coccidioidin tests were normal. Sputum studies were normal. Leukocyte count was 5,400 with 1% Eosinophiles. A thoracotomy revealed a firm fluctuant cyst which was removed by wedge resection. Sections (Fig. 2) revealed a hydatid cyst with typical brood cysts and hydatid sand. The subsequent course has been uneventful.

SYMPTOMATOLOGY

The symptoms are dependent upon the location of the fluctuant, slow growing hydatid, which may cause hepatomegaly, ascites prominent abdominothoracic veins. Nausea, vomiting, constipation, a sense of weight and pressure, hydatid thrill, egg-shell crackling and hypersensitivity occur at times. Pulmonary symptoms may be bile in the sputum, hemoptysis, chest pain and dyspnea. Other organ involvement gives symptoms according to the system.

DIAGNOSIS

The presumptive diagnosis of Echinococcosis may be made by the occurrence of large fluctuant masses. This is confirmed by the finding of scolices, brood capsules, or daughter cysts after surgical extirpation.

Hydatid elements may be found in the sputum.

The Cosoni or von Pirquet cutaneous test consists of intradermal injection of hydatid antigen.

A peripheral Eosinophilia frequently occurs.

Roentgenographic evidence of a unilocular, round, homogenous density with a sharp outline which is seldom completely spherical is very suggestive. There may be a pneumonitis or a characteristic crescentic air space between the parasite and adventia.

The hemagglutination and Bentonite flocculation tests used by the United States Communicable Health Laboratory are two very fine serologic procedures (12).

TREATMENT

Wide surgical removal is the therapy of choice. When the cyst is unilocular, to avoid rupture, the fluid may be aspirated and replaced by 2% formalin for 5 minutes before removal. Multiple operations through the years may be anticipated when there are multiple cysts. Calcified cysts may be followed radiologically and by laboratory tests for signs of activity.

Irradiation is helpful at times when massive ascites develop. Drug therapy has never been of value. Furazolidin has been used with questionable success in one case herein reported.

DISCUSSION

Hydatid Disease or Echinococcosis is the most seri-

ous tapeworm disease of man. Rare in North America, only about 40 autochthonous cases have been reported in the medical literature. There is no entirely satisfactory treatment, full resection being the most satisfactory. One case in this series was treated with Furazolidin, with possible cure. Calcification of a hydatid is sought, rendering spread unlikely.

Awareness of the disease may uncover more patients with hydatidosis. Certainly endemic foci exist in this area, and where endemicity persists, clinical cases may be found.

SUMMARY

The parasitology, clinical course, morbid anatomy, treatment of hydatid disease are discussed.

Three cases of autochthonous Hydatid Disease from Middle Tennessee are reported. Previously only about 40 cases had been found in the medical literature.

LITERATURE CITED

- (1) Tropical Health, A Report on a Study of Needs and Resources. Publication 996, National Research Council, National Academy of Sciences, Washington, D. C. 1962.
- (2) Katz, A. M. and Pan, C. 1958. Echinococcus Disease in the United States. *Am. J. Med.* 25:759.
- (3) Personal Communication, Department of Vital Statistics, Tennessee Department of Health.
- (4) Case Records of Massachusetts General Hospital. 1956. *N. Eng. J. Med.* 255:1247-1250.
- (5) Smith, E. M. G. and Hanson, S. 1961. Alveolar Echinococcosis, Case Report with Discussion of Ecology of Disease. *Am. J. Clin. Path.* 35:160-165.
- (6) La Fond, David J., Thatcher, Donald S. and Handeyside, Robert G. 1963. Alveolar Hydatid Disease. *J. A. M. A.* 186:35-37.
- (7) Betts, R. H. and Thomas, T. 1954. The Treatment of Intra-thoracic Hydatid Disease. *Dis. of Chest.* 26:584.
- (8) Wordle, R. A. and McLeod, J. A. *The Zoology of Tapeworms.* The University of Minnesota Press, Minneapolis, 1952.
- (9) Bailenger, J. 1957. *Bull. Soc. Pathol. Exotique.* 50:308-314.
- (10) Swellengrebel, N. H. and Sterman, M. M. *Animal Parasites in Man,* D. Von Nostrand Co., Princeton, N. J., 265-282, 1961.
- (11) Dévé, F. *L'Echinococcosse Primitive,* Masson & Cie, Paris, 1949.
- (12) Kagan, Irving C. 1963. Seminar on Immunity to Parasitic Helminths. *Exp. Parasitology.* 13:57-71.

NEWS OF TENNESSEE SCIENCE

(Continued from Page 112)

The American Museum of Atomic Energy in Oak Ridge has continued to prove its popularity as one of East Tennessee's major free tourist attractions by setting another attendance record of 132,020 visitors for the fiscal year July 1, 1963-June 30, 1964. The figure is almost 10,000 higher than the previous high of 122,346 set in the fiscal year ending June 30, 1963. The new record includes an all-time high daily attendance of 1642 visitors on August 20, 1963. Comparative figures cite 17,230 visitors to the Museum in June of this year, as compared with 17,049 for June 1963. This June attendance included visitors from 47 states and 22 foreign countries, according to the Museum's visitors' register.

Dr. William H. Adams, Professor of Biology at Tennessee Wesleyan College, has been awarded a \$12,990 grant by the National Science Foundation for the continuation of a six-county Cooperative College-School Science Program for high school biology teachers. Tennessee Wesleyan College also has been awarded a \$16,000 matching grant by the National Science Foundation for the purchase of undergraduate instructional scientific equipment.

Dr. Adams accepted a position as Dean of the School of Arts and Sciences at Tennessee Polytechnic Institute effective September 1, 1964.

(Continued on Page 124)