



Fig. 2. Larval *Clonostomum*, seen with spine-like projections at anterior extremity (taken at 200x).

In October 1967 a sample from Tennessee River mile 286.6, Wheeler Reservoir, Alabama, revealed six specimens of *Clonostomum avellanis* (Hagen) larvae. The largest specimen was 4 mm in length. Specimens were found on colonies of *Spongilla* sp. On November 15, 1967, a specimen of *Clonostomum avellanis* was collected at Clinch River, mile 44.3, Tennessee, from *Spongilla* sp. These are the only locality records known for *Sisomidae* in the Tennessee River drainage.

LITERATURE CITED

Brown, H. F. 1952. The life history of *Clonostomum avellanis* (Hagen), a Sessile Parasitic of Fresh Water Sponges. The Amer. Midl. Nat. Vol. 47: 1 - pp. 130-140.

JOURNAL OF THE TENNESSEE ACADEMY OF SCIENCE
Volume 43, Number 4, October, 1968

THE BROWN RECLUSE SPIDER
AND LOXOSCELEMISM IN TENNESSEE

H. B. REED, JR.
Middle Tennessee State University,
Murfreesboro, Tennessee 37130

ABSTRACT

Fifty-one specimens of the brown recluse spider *Loxosceles reclusa* were collected in Middle Tennessee from July 21 through September 24, 1967. Early additional reports of occurrence were investigated. Distribution of the spider is reported for 9 counties of West Tennessee, 16 counties of Middle Tennessee and 3 counties of East Tennessee. All inhabited sites observed by the author or reported to him were within or near buildings. One confirmed case of brown recluse spider bite (Lomax 1961) and a number of suspected cases are reported.

INTRODUCTION

The medical importance of certain spiders of the genus *Loxosceles* has attracted attention since 1934 when Macchiavello (in Gertsch 1967) demonstrated that a South American species, *L. lacta*, causes a severe cutaneous necrosis in man. Currently three additional species (*L. guscha*, *L. reclusa* and *L. rufescens*) are

known to be venomous and it seems probable that all species of the genus are toxic (Gertsch 1967). Descriptions of the syndrome are given by Lessenden and Zimmer (1960) and Dillaha et al. (1964). Denny et al. (1964) have made in vivo and in vitro studies of the hemotoxic effect of the venom. Taylor and Denny (1966) give a case report of hemolysis, renal failure and death, presumed secondary to the bite of *Loxosceles reclusa*. Five deaths from apparent loxoscelism have been reported in the United States (Presley 1896, Lessenden and Zimmer 1960, Nicholson and Nicholson 1962, Taylor and Denny 1966, Anonymous 1968).

The loxoscelines possess six eyes, in three diads, in contrast to the total of eight eyes possessed by most

spiders. Gertsch (1955, 1967) has reviewed the taxonomy and biology of the American species of the genus. Of the five species which occur in the United States, only *Loxosceles reclusa* (Fig. 1) and *L. rufescens* are reported in the Southeast. The latter species has a sporadic distribution and has not been recorded in

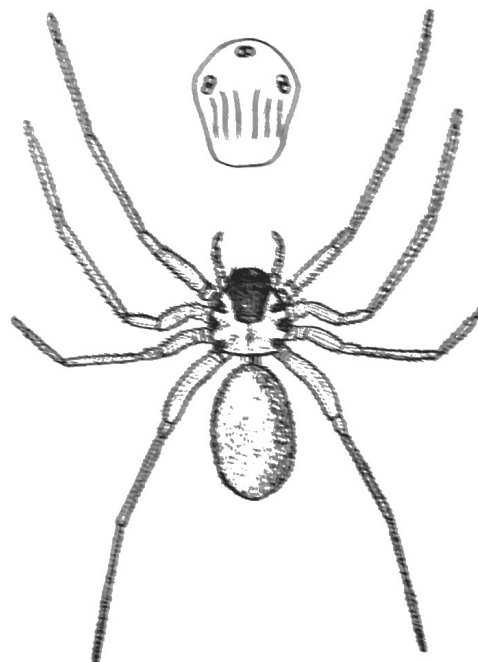


Fig. 1. Adult female of *Loxosceles reclusa*. Inset at top shows position of eyes anterodorsally on cephalothorax. (From Scott and Stojanovich 1963).

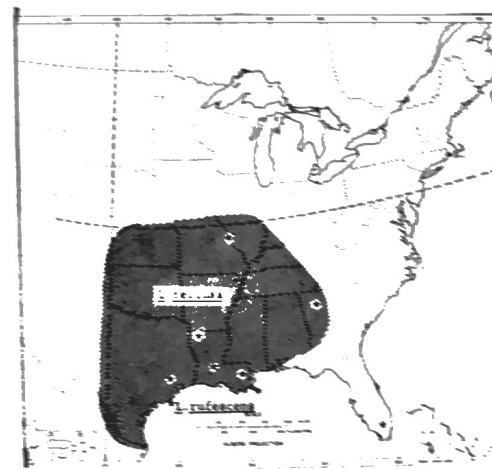


Fig. 2. Approximate range of *Loxosceles reclusa* in the United States. (From Wingo 1964).

Tennessee. Hite et al. (1966) discuss the biology of *L. reclusa* and Wingo (1964) presents a map showing the approximate distribution of this species in the United States (Fig. 2). According to popular misconception the spider is a recent invader of Tennessee. Adult specimens are approximately 5 to 9 mm in length. The most distinguishing mark is the dark violin-shaped band on the anterior portion of the carapace.

This report presents a discussion of the biology and distribution of the brown recluse spider, *Loxosceles reclusa* Gertsch and Mulak, and bites received from it in Tennessee. The principal information relating to the biology of the species was secured in Rutherford County, Tennessee.

MATERIALS AND METHODS

Fifty-two specimens of *Loxosceles reclusa* were examined: fifty from Rutherford County; one from Marshall County; and one from Lewis County. All but one of the specimens were collected during the interval from July 31 through September 24, 1967. Specimens were preserved in an ethanol-formalin solution as recommended by Kaston (1953). The adults were confirmed as being *L. reclusa* according to the male palpal characteristics and female seminal receptacle shapes as described by Gertsch (1955). The immatures were presumed to be *L. reclusa* instead of *L. rufescens*. I was unable to confirm their specific identity due to absence of the diagnostic adult genital structures.

Adult males were distinguished by the presence of the copulatory organ on the distal palpal segment. Penultimate (last instar preceding the adult) males have the palpal tarsus slightly swollen by the developing copulatory organ within. Adult females were distinguished by the heavier sclerotization of the lips of the genital groove, by the darker coloration of this area and by the presence of heavier setae, particularly along the groove (Gertsch 1955). The earlier male and female instars have unswollen palpi and I was unable to determine the sex of such specimens.

RESULTS

THE ORGANISM

Of the twenty adults of *Loxosceles reclusa* collected, 13 were females and 7 were males (Table 1). The adult females averaged 8.9 mm long and the adult males 9.3 mm long. The carapace showed little variation in color among the larger immatures and the adults. In all cases it had waxy gloss, appeared to be translucent for a slight depth and, except for the darker markings, was generally of a light pinkish tan color. Gertsch (1955), referring to specimens collected in a variety of areas, describes the integument of the carapace as being pale yellowish to quite dark orange or reddish brown and marked with darker pattern.

of the spiderlings or, in two instances, the spiderlings themselves.

During the late summer of 1967 several specimens were found in and under cabinets, book cases and boxes in the Old Science Building at Middle Tennessee State University. Shed cuticles and webs were found in protected areas within and under such objects. In my own home I found several specimens hidden under articles in the attic and in rooms; one specimen was found under the carpet and one on the front porch.

LOXOSCELIISM IN TENNESSEE

Brief data concerning one confirmed and a number of suspected cases of loxoscelism in Tennessee are given in Table III. This table probably lists only a small proportion of the total number of cases which have occurred within recent years.

TABLE III
SOME CONFIRMED AND SUSPECTED CASES OF
LOXOSCELIISM IN TENNESSEE¹

Date of Bite	Location	No. of cases	Reporting Individual
July 16, 1958	Rutherford Co.	1	S. C. Garrison ^d
ca. Nov. 10, 1958	Middle Tenn.	1	W. E. Nance ^b
ca. Nov. 27, 1958	Middle Tenn.	1	W. E. Nance ^b
Dec. 20, 1964	Humphreys Co.	1	Patient
July 12, 1967	Dickson Co.	1	Patient
ca. July 28, 1967	Rutherford Co.	1	Patient
Aug. 15, 1967	Wilson Co.	1	R. S. Sanders ^d
1958-1967	Middle Tenn.	ca. 6	S. C. Garrison ^b
Summer 1967	East Tenn.	1	Robert Lash ^b
Recent years	West Tenn.	Many	O. E. Smith, Jr. ^e

¹ The July 16, 1958 case of Dr. S. C. Garrison is the only case in which, to my knowledge, the offending spider was identified.

^b Attending physician.

^c W. E. Nance. 1961. Hemolytic anemia of necrotic arachnidism. *Amer. J. Med.* 31:801-7.

^d County health officer.

^e These cases were seen by Dr. Garrison and two of his associates in practice.

^f Medical entomologist, Memphis State Univ.

Dr. Garrison's patient, a 39 year old woman living in a rural area of Rutherford County, was bitten on the back during the night of July 16, 1958. When the patient was first seen by the physician two days later a blister 1 cm in diameter was present, surrounded by a zone of erythema. The patient had experienced a flushed feeling of the face on the previous day and complained of headache and malaise. She was slightly hoarse. By July 19 a hemorrhagic spot was present, which by July 25 had developed into an ecchymotic area about 2 x 4 cm. The ecchymotic area was interrupted by numerous small vesicles and there was a zone of induration 3-4 cm wide surrounding this area. On August 8 the lesion was healing. Treatment included seven intramuscular injections of 40 units each of repository adrenocorticotrophic hormone given over a period of ten days. The spider was captured by the patient and given to the physician. It was subsequently identified as a penultimate female of *Loxosceles reclusa*.

DISCUSSION

In previous years in the United States most curricula incorporating some instruction concerning venomous arthropods have devoted little attention to the genus *Loxosceles*. Of the widely used textbooks in the field only those more recently published include discussions of any species of the genus. There has been little effort to promote widespread alertness to presence of the brown recluse in Tennessee.

Its nocturnal habits, reclusiveness, innocuous appearance and the small likelihood that it will be seen after having bitten a person have caused it to attract very little attention. The last of these attributes has doubtless hindered specific diagnoses in the past.

Possibly as further reports of the spider are received from various parts of the state, more reports of its occurrence outdoors will be received. Apparently the spider occurs less frequently outdoors in most parts of Tennessee than it does in Arkansas and southern Missouri. If this is true, it would seem that the determining factors would be other than climatic since the climates of the areas in question are not greatly different (see U.S. Department of Agriculture 1941 and Visher 1954). Possibly the spider originally spread into Tennessee by way of domestic introductions and exhibits inability to invade rapidly the outdoor habitat.

ACKNOWLEDGEMENTS

Appreciation is expressed to Drs. S. C. Garrison, W. J. Gertsch, R. S. Sanders, and to the many other people who furnished information embodied in this paper.

LITERATURE CITED

- Anonymous. 1968. Death blamed on recluse spider. *Sci. News* 93:106.
- Denny, W. F., C. J. Dillaha, and P. N. Morgan. 1964. Hemotoxic effect of *Loxosceles reclusus* [sic] venom: in vivo and vitro studies. *J. Lab. & Clin. Med.* 64:291-298.
- Dillaha, C. J., G. T. Jansen, W. M. Honeycutt, and C. R. Hayden. 1964. North American loxoscelism. *JAMA* 188:33-36.
- Gertsch, W. J. 1958. The spider genus *Loxosceles* in North America, Central America, and the West Indies. *Amer. Mus. Novitates*, no. 1907. 46 p.
- _____. 1967. The spider genus *Loxosceles* in South America (Araneae, Scytodidae). *Bull. Amer. Mus. Nat. Hist.* 136: 119-173.
- Hite, Julia M., W. J. Gladney, J. L. Lancaster, Jr., and W. H. Whitcomb. 1966. Biology of the brown recluse spider. *Univ. of Arkansas Agr. Exp. Bull.* 711. 26 p.
- Kaston, B. J. 1953. How to know the spiders. Wm. C. Brown Co., Dubuque, Iowa. 220 p.
- Lessenden, C. M., Jr., and L. K. Zimmer. 1960. Brown Spider bites. *J. Kansas Med. Soc.* 61:379-385.
- Nance, W. E. 1961. Hemolytic anemia of necrotic arachnidism. *Amer. J. Med.* 31:801-807.
- Nicholson, J. F., and B. H. Nicholson. 1962. Hemolytic anemia from brown spider bite. *J. Oklahoma Med. Assoc.* 55:234-236.
- Norment, B. R. 1966. Some aspects of the ecology and toxicology of *Loxosceles reclusa*. M. S. Thesis. Memphis State Univ., Memphis, Tenn. 46 p.
- Presley, J. E. 1896. A case of spider bite. *Memphis Med. Monthly.* 16:520-522.
- Scott, H. G., and C. J. Stojanovich. 1963. Spiders: key to some important United States species. U. S. Dept. of Health, Educ., and Welfare, Public Health Serv., Communicable Disease Center, Atlanta, Ga. 1 p.
- Taylor, E. H., and W. F. Denny. 1966. Hemolysis, renal failure and death, presumed secondary to bite of brown recluse spider. *Sou. Med. J.* 59:1209-1211.
- U. S. Department of Agriculture. 1941. Climate and man. U. S. Government Printing Office, Washington, D.C. 1248 p.
- Visher, Stephen Sargent. 1954. Climatic atlas of the United States. Harvard University Press, Cambridge. 403 p.
- Wingo, C. W. 1964. The status of *Loxosceles reclusa*, the brown recluse spider, as a public health problem. *Proc. No. Central Branch, Ent. Soc. Amer.* 19:115-118.